

## Fetal Mummification in a Bitch

Qazi Mudasir\*, K. A. Shah, Qazi Nyrah<sup>1</sup> and Anjum Andrabi

*The article reports a case of mummification in bitch involving one mummified fetus successfully removed through caesarean operation and one live fetus delivered through normal parturition.*

### KEYWORDS

Mummification, pup, bitch, cesarean operation.

### INTRODUCTION

Death of the fetus after ossification of fetal bones generally leads to fetal mummification if there is no bacterial infection concurrent with or causing death of the fetus (Robinson et al, 2003). The uterus contracts on the fetus, placental fluids get absorbed and fetal membranes become shriveled and dried (Roberts, 2004). Fetal mummification is a common problem in polytocous and rare in monotocous animals (Perumal and Srivastava, 2011). In polytocous species, if mummification occurs in some embryos, it does not interfere with continuation of pregnancy of viable fetus; instead mummified fetus may be delivered with live fetus at the time of normal parturition (Arthur et al., 2001).

Presents communication describes removal of mummified fetus by cesarean operation in a Pomerian bitch that had earlier delivered one live fetus normally.

### MATERIALS AND METHODS

A 6 year old Pomerian bitch was presented to Central Veterinary Hospital Srinagar for pregnancy checkup with the history that bitch had

Animal Husbandry Department, Kashmir, Srinagar

1 – MVSC Scholar, SK University of Agricultural Sciences and Technology of Kashmir.

mated 59 days prior. Clinical and ultrasonographic examination of the animal was conducted to ascertain pregnancy status. Expulsion of the mummified fetus was unsuccessfully attempted by administering Estrogen 2mg and Oxytocin 10 IU intramuscularly. A caesarean section was performed for removal of the mummified fetus. Pre-operatively the animal was administered Atropine sulfate @ 0.04 mg/kg body weight and anaesthesia was achieved using xylazine @ 1mg/kg body weight IV and ketamine @ 5 mg/kg body weight IV. After preparation of surgical site cesarean operation was performed in routine manner and one mummified fetus was delivered (Fig.1). The peritoneum and muscles were sutured using vicryl no: 1 with two rows of simple continuous sutures and skin was sutured with silk thread using crossed mattress suture. The post-operative care involved Injecting Ceftriaxone 500 mg (I/M) twice daily, Inj. Meloxicam 1.5ml (I/M) once daily for five days in addition to fluid therapy (Inj. DNS) 500 ml I/V for two days. Daily dressing was done using Ointment Neosporin and sutures were removed on 10th postoperative day.

### RESULTS

Ultrasonographic evaluation on 59th day of pregnancy revealed presence of one live fetus with presence of heart beats and differentiation into fetal skeleton and other organs. The other fetus was small and contracted with faint mineralization but without any heart beats and differentiation into fetal organs. Hence it was diagnosed as a case of fetal mummy along with normal live fetus within the uterus.

One live fetus was delivered at the time of normal parturition but the other mummified fetus did not

expel even after waiting for one hour. Fresh ultrasonographic examination was conducted which revealed presence of mummified fetus within the uterus and it was later removed by cesarean operation. The post-operative recovery was uneventful.

#### DISCUSSION

Presence of one or more mummified fetus in the uterus along with normal live fetus is observed occasionally in dogs (Roberts, 2004). In the present case mummified fetus was detected along with the normal live fetus in the gravid uterus of bitch. Only the live fetus was normally delivered and the main reason for lack of expulsion of mummified fetus at the normal time of parturition may be primary uterine inertia which is common in canine species. Walett and Linde (1994) and Romagnoly et al. (2004) have also reported uterine inertia as main cause of dystocia and retention of mummified fetus in bitches.

In the past delivery of mummified fetus along with normal live fetuses at the time of parturition has been reported in canines by Prabhakar et al (1993) and Srivastava (2005). Similar finding was reported in swine and feline by Arthur et al., (2001).

#### ACKNOWLEDGEMENT

Authors are highly indebted to Superintendent, Central Veterinary Hospital Srinagar for providing necessary facilities.

#### REFERENCES

1. Arthur, G.H., Noakes, D.E., Pearson, H. and Parkinesen, T.J.(2001). Veterinary Reproduction and Obstetrics.W.B.Saunders Company Limited.London. p137
2. Perumal,P. and Srivastava, S.K.(2011) Mummified foetus and a pup with eviscerated intestines in normal litter at term in a pug bitch.Indian Pet Journal.10

3. Roberts, S.J.(2004).Veterinary Obstetrics and Genital Diseases. C.B.S. Publishers and Distributors.Delhi.p170
4. Robinson. I., Wayne.F. and Clive. R.R. Hextable (2003). Clinico-pathologic Principles of Veterinary Medicine. Published by the Press Syndicate of the University of Cambridge, Trumpington Street, Cambridge, U.K. P136
5. Prabhakar S, Gandotra VK, Shrama RD. (1993). Fetal mummification in bitches. Indian Veterinary Journal, 70: 371-372.
6. Romagnoly S., Desouza F.F., Rota A., Vannozzi I (2004). Prolonged interval between parturition of normal live pups in the bitch. Journal of Small Animal Practice. 45:249-253
7. Srivastava, S.K. (2005).Clinical management of mummified fetus in a bitch. IndianVet.J.82:1208-1209
8. Walett, D and Linde, F. (1994). Dystocia in the bitch- a retrospective study of 182 cases. Journal of Small Animal Practice, 35(8):402-407

---

\*Address for correspondence:

Qazi Mudassir\*, Animal Husbandry Department, Red Cross Road, Gaw Kadal, Srinagar, Kashmir 190001, India.  
e-mail address: qazimude@gmail.com

FIGURES

Fig.1: Mummified fetus removed after cesarean section.

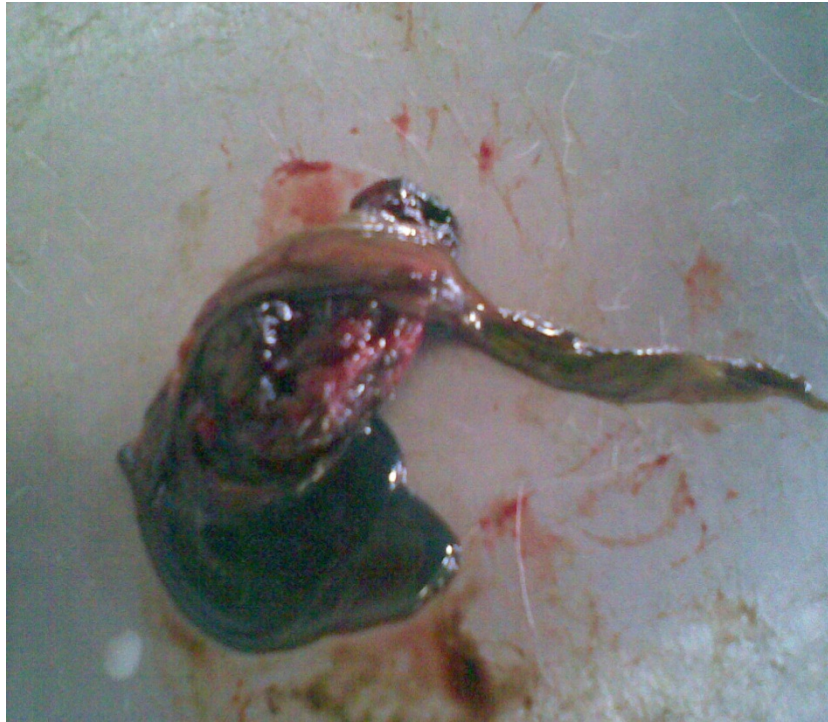


Fig.2: Normal pup along with mummified fetus.

